

Instrument fracture removal revisited

Authors_ Drs Dominique Martin & Pierre Machtou, France

Introduction

The fracture of a root canal instrument during endodontic treatment is quite a common occurrence. The estimated risk of instrument fracture is between 0.5 and 5 per cent.¹⁻⁶ It has been shown that the number of instrument fractures has notably increased with the growing use of rotary instruments made of nickel titanium (NiTi).^{2,4}




Fig. 1

Fig. 1_ The Endo Rescue Kit (Komet).

Procedures to remove instrument fragments have been used for many years, but the introduction of operatory microscopes to clinical practice has led to a completely new approach. The possibility of actually seeing the instrument allows a far more effective procedure, which is further helped by the development of instruments specially designed for this purpose. These techniques are now well documented, and studies evaluating the possibilities of removing instrument fragments have shown encouraging results.⁷⁻¹⁰ The most common technique entails preparing straight-line access to the coronal part of the fragment using Gates Glidden drills, creating a staging platform with a modified Gates Glidden drill, and then using thin ultrasonic tips to retrieve the fragment from the canal walls through ultrasonic vibration.¹¹

Although this technique is very effective, it has some disadvantages:

It requires great skill from the operator, since the procedure is done under high magnification. In addition, it is difficult to trough around the fragment without touching it. Especially in the case of an NiTi broken instrument, the fragment may fracture during the course of treatment if the ultrasonic tip contacts the instrument too early or if not enough space is available around it.¹²

Often, too much radicular dentine structure is removed, which is likely to weaken the root.¹³

In order to improve visual control, the treatment is carried out without irrigation, potentially leading to an increase in temperature of the periodontal tissue.^{14,15} Work therefore must be interrupted regularly to control heating and provide cooling.

The procedure is fairly time consuming. The estimated time required for the treatment was shown to be between 40 and 55 minutes.¹⁶

An alternative method is to remove the fragment with the micro-tube technique. Several variations of this technique have been described, including the Masserann Micro Kit (MICRO-MEGA),¹⁷ the IRS (DENTSPLY Maillefer),¹⁸ and a micro-tube coupled with a Hedstroem file.⁹ The use of tubes and cyanoacrylate glue (Cancellier Kit, SybronEndo) or composite self-curing resin¹⁹ are other methods to retrieve the fragment.

The present technique is a combination of the trephine drill technique using a new device, the Endo Rescue Kit (Komet Dental), and the micro-tube technique using dedicated needles and composite self-curing resin. The main goal of this technique is to be the least destructive as possible for the tooth structure. The aim of the present study was to assess the success rate of this micro-endodontic removal technique and compare the results with those of published studies.

Fig. 2

Fig. 3

Materials and methods

This clinical endodontic study was conducted in a specialist endodontic practice by one operator. The inclusion criterion was a fractured instrument located in a tooth referred for endodontic retreatment. The case was either specifically referred for instrument removal or a fracture occurred during endodontic treatment in the operator's practice. The exclusion criterion related to the possibility of safely accessing the fragment. When it was not possible to create straight-line access to the coronal part of the fragment or when such access would have been too destructive to the tooth structure, the case was excluded from the study and removal of the fragment not attempted. All cases were treated according to the same procedure using the Endo Rescue Kit following the Masserann's basic approach, which involves removal of dentine around the fragment with trephine drills. However, this new kit differs from the Masserann Micro Kit.²⁰ The first instrument is a special centring drill featuring a concave active surface (Fig. 1) whose diameter matches precisely the size of the corresponding trephine (Fig. 2). The centring drill prepares the site for the subsequent use of the trephine. Three trephine sizes are available. The smallest trephine has an external diameter of 0.7 mm (corresponding to a #2 Gates Glidden drill), the size of the next one is 0.9 mm (corresponding to a #3 Gates Glidden drill) and the last one is 1.1 mm (corresponding to a #4 Gates Glidden drill).

The following steps were followed in a strict sequence:

1. Similar to the currently used techniques, straight-line access to the coronal portion of the fractured instrument has to be created. The goal of this step is to visualise the fractured instrument under the op-

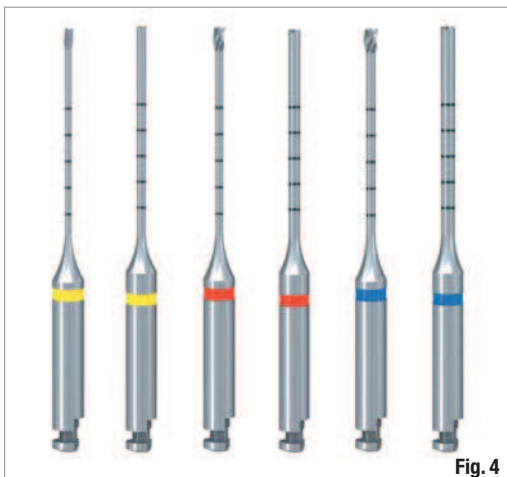


Fig. 4

erating microscope. A cylindro-conical bur with a non-cutting tip (Komet Dental) was used to refine the access cavity walls, followed by the use of a short #4 Gates Glidden drill (Komet Dental) to relocate the canal orifice away from the furcation. Direct access to the fragment was then created with a #2, 3 or 4 Gates Glidden drill, depending on the diameter of the coronal part of the fragment and its location within the canal.

2. The centring drill, whose external diameter matches precisely the size of the previously used Gates Glidden drill, removes dentine around the fragment. Its concave active surface, when coming into contact with the fragment, allowed good centring of the preparation around the coronal part of the fragment.

Teeth	n	Removed	Not removed	Success (%)
Incisors	1	1	0	100
Upper premolar	6	6	0	100
Lower premolar	0	0	0	0
Upper molar buccal root	8	7	3	70
Upper molar palatal root	1	1	0	100
Lower molar mesial root	13	11	4	73
Lower molar distal root	3	3	0	100

Fig. 2_Centring drill.

Fig. 3_Trepine.

3. The corresponding trephine was placed in the area previously prepared with the centring drill to free the fragment by removing the surrounding dentine. The trephine was used in a handpiece at a low speed (300 rpm) in an anti-clockwise rotation or by hand (Figs. 1 & 3).

4. When the fragment could not be removed with the trephine alone, the Endo Rescue Kit was used in combination with a needle filled with a self-curing composite. A needle (Ultradent) with the same external diameter as the trephine was filled with a self-curing composite core material and placed on to the free portion of the fragment. Once the composite had set, the needle was removed with an anti-clockwise motion (Fig. 2). A radiograph was taken to confirm that the instrument had been successfully removed. Complete removal of the fragment without creating a perforation was defined as a success.

The distribution of fractured instruments among different root types (i.e. anterior teeth, premolars, buccal roots of maxillary molars, mesial roots of mandibular molars, distal roots of mandibular molars, and palatal roots of maxillary molars) was recorded, as well as the anatomical location of the fractured instruments (i.e. coronal part of the fragment in the coronal third, middle third or apical third).

Table 1_Success rate depending on the type of tooth.

Fig. 4_Different sizes of centring drill and trephine: the smallest has an external diameter of 0.7 mm (corresponding to a #2 Gates Glidden drill), the size of the next one is 0.9 mm (corresponding to a #3 Gates Glidden drill) and the last one is 1.1 mm (corresponding to a #4 Gates Glidden drill).

Position	n	Removed	Not removed	Success (%)
Coronal third	5	5	0	100
Middle third	18	16	2	89
Apical third	8	8	5	61

Table 2_Success rate depending on the level of the fragment.

_Results

Success or failure rate

According to the inclusion criterion, 36 fragments were recorded within the 18-month period, involving 32 teeth in 30 patients. Five instruments were excluded because straight-line access to the fragment was deemed impossible. Therefore, no attempt was made to use the described technique. Thus, the technique was used for 31 instruments, 29 of which were removed successfully. Of those, 19 were removed with the trephine alone and ten with a needle filled with composite resin (Table 1). This resulted in a success rate of 93.5%. Two instruments (6.5%) further fractured on attempted removal, leaving the most apical part in the canal. No perforation of the root walls was noted.

Case 1: Fragment removal with the ø 90 Endo Rescue Kit.

Fig. 5a_Pre-operative X-ray of tooth #26 showing a fractured instrument located in the middle part of a MB curved root canal.

Fig. 5b_Trephine size 90 surrounding the fragment.

Figs. 5c-d_Fragment locked inside the trephine and removed from the canal.

Fig. 5e_Final X-ray.

Type of tooth and root

There were 24 instrument fragments found in 21 molar teeth (75% of the sample). There were six premolars with six fragments (accounting for 21.4% of the teeth) and one incisor with one fragment (accounting for 3.6% of the teeth).

The two failures occurred in a mesial root of a molar, one in a mesial root of a mandibular molar and one in a mesiobuccal root of a maxillary molar (Table 2).

Location of fragments in root canal

It is important to note that it was the location of the coronal part of the fragment that was recorded. All instruments that had fractured in the coronal third ($n = 5$) were removed from the root canal. All removal failures ($n = 2$) occurred in situations in which only the head of the fragment was visible but the main portion of the fragment was located beyond a sharp curvature. In these two cases, the instrument fractured again, leaving the most apical part in the canal.

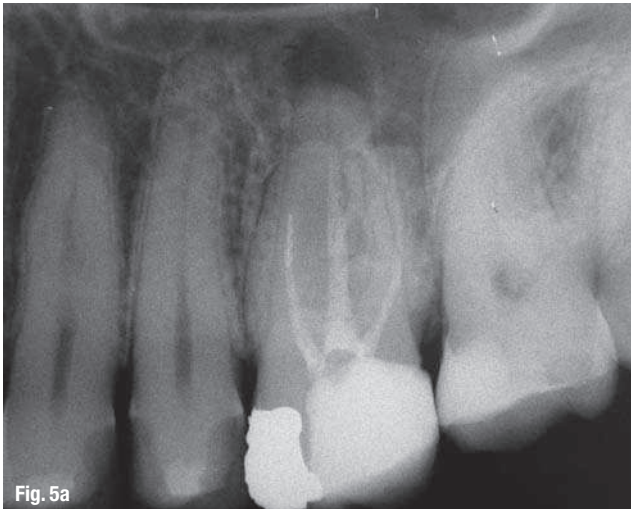


Fig. 5a

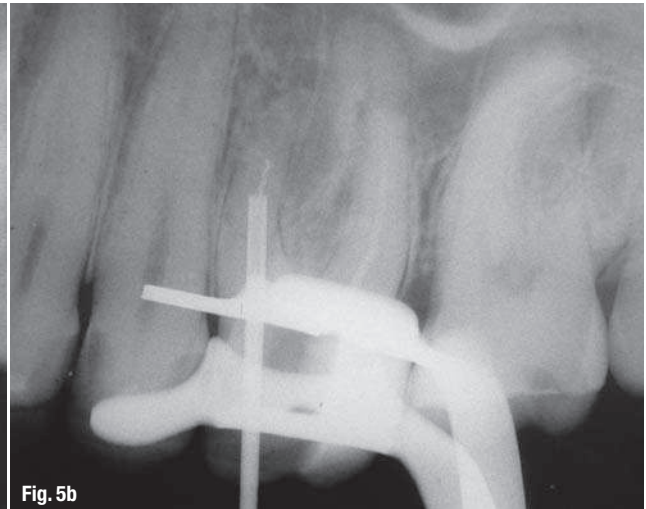


Fig. 5b

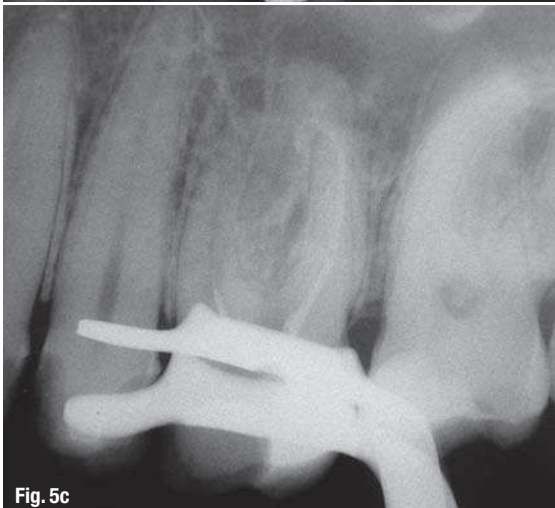


Fig. 5c



Fig. 5d

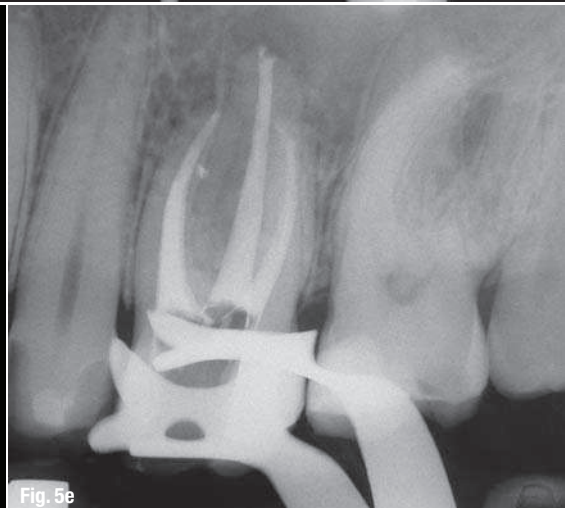
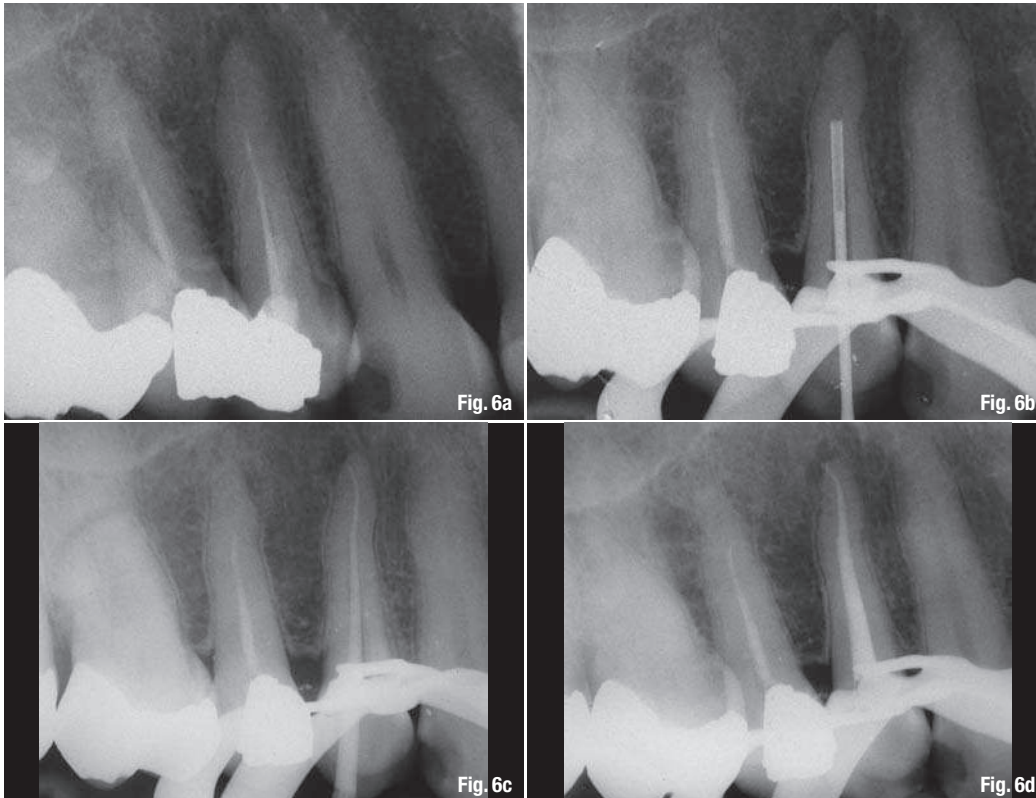


Fig. 5e



Case 2: Fragment removal with the ø 70 Endo Rescue Kit trephine.

Fig. 6a_Pre-operative X-ray of tooth #25, featuring a long and narrow root with a very thin fragment fractured at the junction between the middle and the apical third of the root.

Fig. 6b_Trephine size 70 surrounding the fragment.

Fig. 6c_The fragment is removed with the trephine, shaping and filling are achieved.

Fig. 6d_Final X-ray showing a minimally invasive procedure.

Discussion

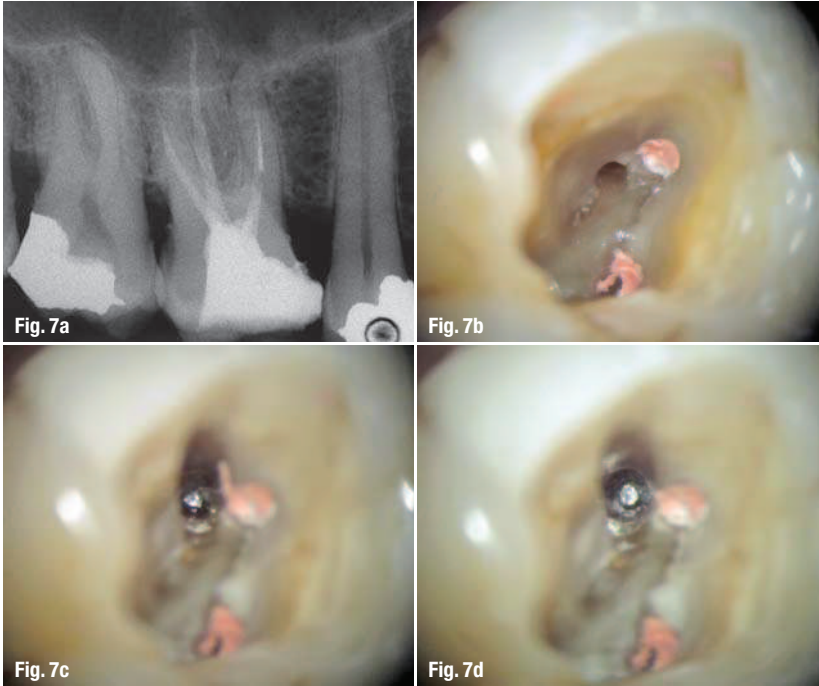
Success rate

The present study is a prospective evaluation of cases referred to a specialist practice and treated under a dental operating microscope. The success rate of removal of the fractured instruments with the described technique was 93.5%.

A variety of different techniques and devices for removal of fractured instruments have been described in the endodontic literature.¹⁵ The majority of these publications involve descriptions of techniques and case reports. To date, there have been only two detailed investigations on the influence of different factors regarding success or failure of removal attempts using micro-endodontic techniques and a dental operating microscope. In these two studies, the success rate for the removal of fractured instruments was reported to be 87%⁹ and 95%,¹⁰ respectively. In Suter's study, various techniques were used to remove the fragments. In Cujé's study, the same procedure was applied using ultrasonic files in all cases. The loss of dentine was not mentioned in either study. In the present study, taking into account the cases for which no attempt at removal was made, the overall success rate was 80.5% and compared favourably with Suter's study. For the 31 cases treated, the success rate was similar to Cujé's study. In the current protocol, the focus was on the preservation of the tooth structure.

Decision-making

The general principle for removing a fractured instrument is based on the fundamental principles and objectives of root canal treatment. A fractured instrument may be an obstacle to mechanical and chemical treatment of an infected root canal system. Bacteria and pulp tissue remaining in the root canal because of insufficient cleaning may have a negative impact on the treatment outcome.²¹ Moreover, the prognosis is likely to depend on the stage and degree of canal preparation and disinfection at the time of instrument fracture and, therefore, on the extent to which microbial control has been achieved.^{1,2} The risk factors associated with the presence of a fragment are not clear. Recently, a systematic review and meta-analysis were performed to determine the outcome difference between retained fractured instrument cases and matched conventionally treated cases. Two case-control studies were identified, covering 199 cases. The risk difference of the combined data indicated that a retained fragment did not significantly influence healing.²² The presence or absence of a pre-operative periradicular disease has been reported to be the main predictive factor for outcome in such cases.^{2,23} The risk-benefit ratio of the two therapeutic options, that is, either leaving the fragment *in situ* and completing the treatment by filling the accessible parts of the canal, or trying to remove the fragment so that the entire canal can be treated, should be carefully assessed for each case.



Case 3: Fragment removal with a needle and composite resin.

Fig. 7a_Pre-operative X-ray of tooth #16. A fractured instrument is located in the middle part of the MB2 canal.

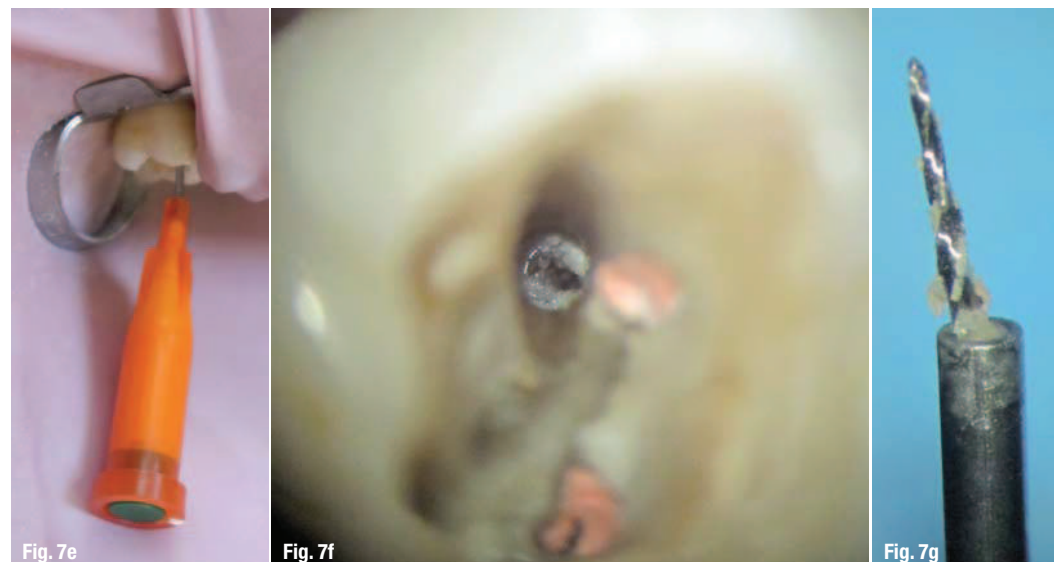
Figs. 7b & c_Relocation of the canal orifice and centring of the preparation after the pointer drill use.

Fig. 7d_The coronal portion of the fragment is freed after the work of the trephine.

Instrument removal itself represents a risk and the decision to remove, or not to remove, a fragment is a difficult one. Depending on the technique used, perforation of the root, ledge formation and transportation of the original canal may occur, as well as weakening of the affected root in case of excessive removal of dentine¹³ or fracture of an additional instrument.^{8,9,23-25} Therefore, when no lesion is present, current knowledge leads us not to attempt a risky procedure to remove the fragment. In this study, five fragments were deeply fractured and not accessible with straight-line access. According to the previous rationale, no attempt was made to remove these fragments, since no apical lesion was present (Fig. 4). Two of these fragments were bypassed and the endodontic treatment completed.

Figs. 7e-h_The needle technique with composite resin inside the lumen is used to remove the fragment.

Figs. 7i_Final view of the completed case.



NiTi fractured instruments

The fracture of rotary NiTi instruments is characterised by certain distinctive features. The first characteristic is that, owing to the rotary movement of the instrument and penetration of the flutes into the walls, the fragment is most frequently blocked in the dentine.²³ The second characteristic of these fractures is related to the instrument design. Most rotary NiTi instruments have a taper greater than 2%. Owing to this increased taper, the coronal part of the fragment is likely to be blocked in the canal, whereas the apical portion remains free. This particular feature of NiTi instruments complicates the primary procedure of removing the fragment, which normally entails passing an endodontic hand instrument between the fragment and the canal walls, and guiding it along the fragment to regain patency of the canal. In this case, a more invasive solution is required. This involves straightening the coronal curve to gain access to the fragment at the expense of the dentinal walls. Such techniques are still very controversial.

A frequent counter-argument is the fact that the root canal is weakened by the removal of dentine during the procedure.^{26,27} This loss of tissue reduces the fracture resistance of the root^{13,28,29} and may lead to complications, such as inadvertent perforation of the root.⁸ Ideally, the dentine should be preserved as much as possible and the extent of the root canal preparation after the removal of the fragment should not exceed that of a conventional preparation. The tested technique is intended to overcome this limitation. Although the use of the Endo Rescue Kit involves the removal of an additional amount of dentine, the small diameter of the instruments keeps the damage to the root structure to a minimum, while creating access to the fragment.

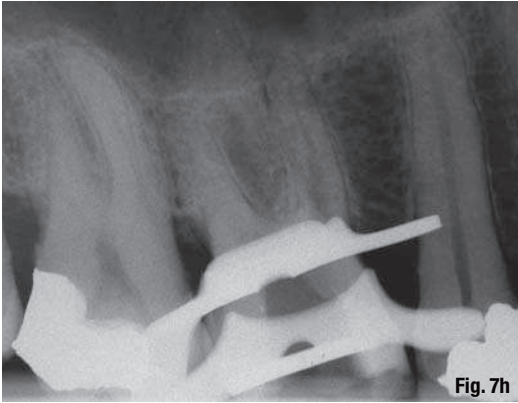


Fig. 7h

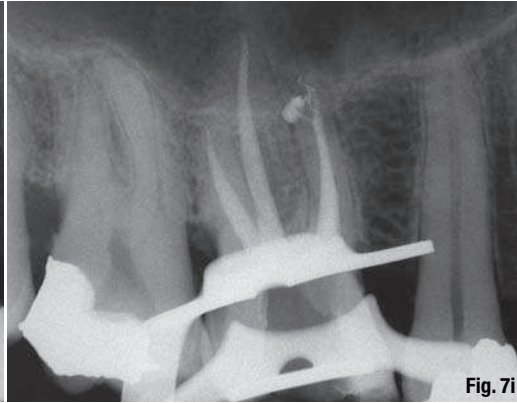


Fig. 7i

Access to the fragment

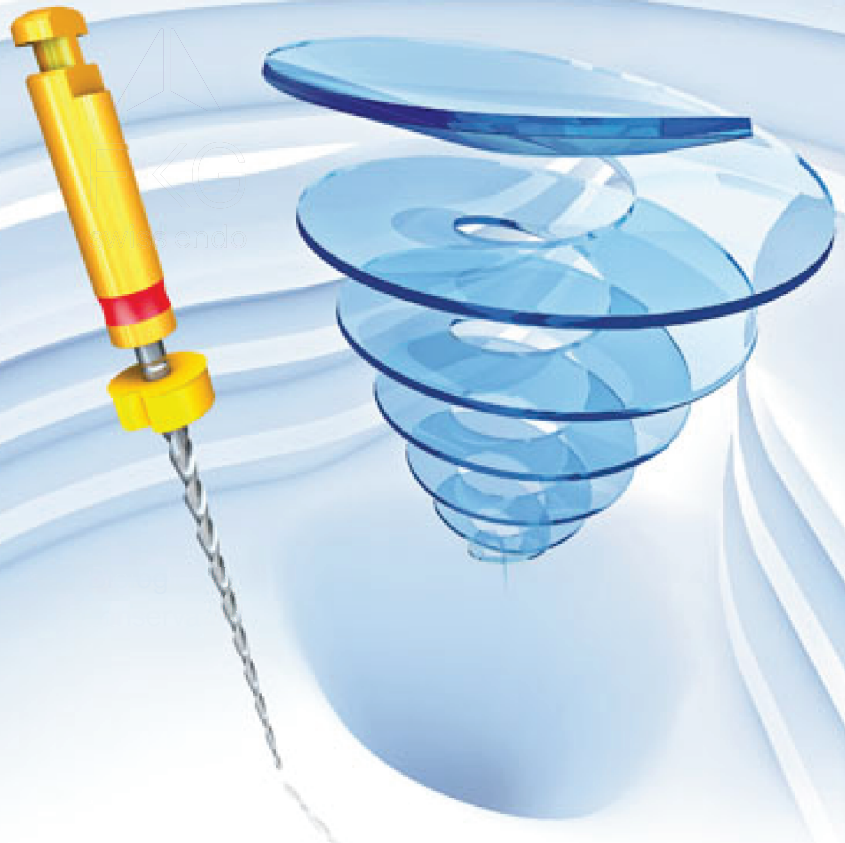As with all the techniques described, the decisive factor for success was to gain direct access to the fragment. Given that the fragment is usually located beyond the curve of the canal, it is essential to straighten the coronal curve in order to create direct access to the fragment and ensure an unobstructed view of it through the operative microscope. It is equally necessary to expose at least 1.5 mm of the fragment with a trephine in order to be able to catch the fragment with a needle filled with composite

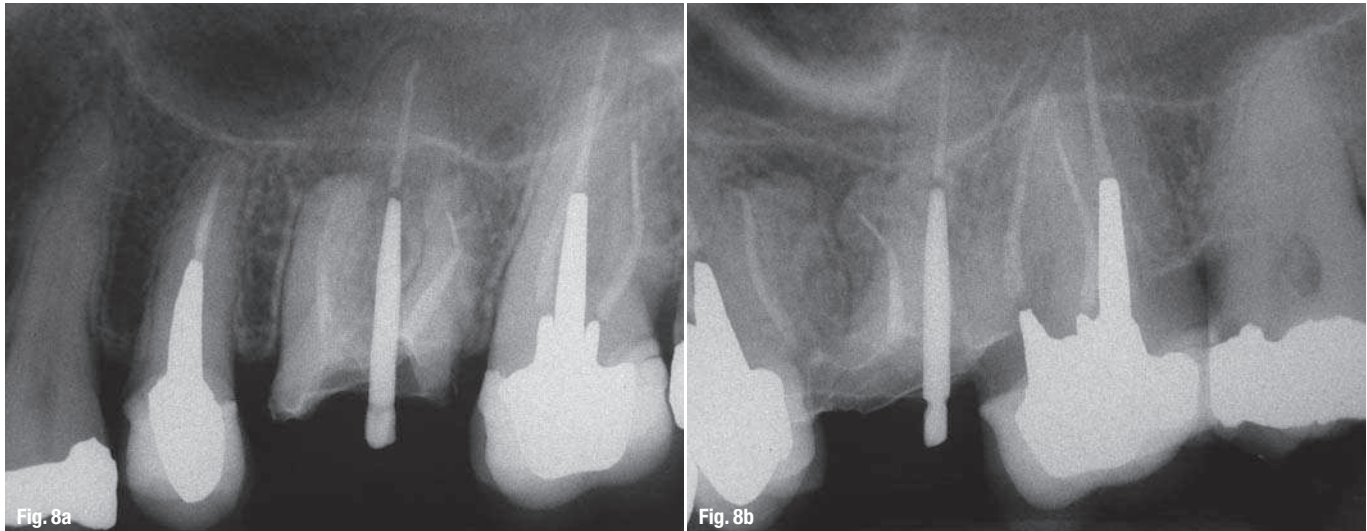
resin. A dilemma exists in such situations because it has not been clearly shown that a retained fragment has any impact on the prognosis,² but there is some evidence that removing tooth structure weakens the tooth. It must be carefully evaluated and critically analysed to determine whether a removal attempt is necessary or indicated in each clinical case.²³ In this study, after the preparation of the coronal access and when no periapical lesion was present, it was decided not to attempt to remove the fragment, as it was not visible under the operating microscope.

AD

F360®.

1ère solution universelle
de préparation canalaire.





Case 4: No removal attempt.
Figs. 8a & b _Fragment located apically beyond the canal curvature of tooth # 26 without radiographic signs.

The second step was to prepare a staging platform around the fragment. By investigating different techniques for preparation of a staging platform, Iqbal et al. found it was increasingly difficult to prepare a platform with a centred fragment owing to the increasing distance between the fractured instrument and the maximum curvature of the root canal.⁴ The modified Gates Glidden drill described in Ruddle's technique is a helpful instrument for preparing the staging platform but it does not allow centring of the fragment.

The design of the centring drill in the Endo Rescue Kit follows the same concept but was modified to have a tapered concave active portion. The outer blades cut into the dentine surrounding the fragment, and the concave tapered area that encounters the coronal part of the fragment allows centring of the preparation by advancing the drill apically. This can be carried out by removing a minimum amount of dentine according to the size of the drill, while working in the centre of the canal (Fig. 8).

The micro-tube technique

The first device to use micro-tubes was the Masserann Micro Kit. This well-known kit is designed to remove all metallic objects from the root canal and consists of a variety of trephines of different sizes and an extractor to grasp the fragment and remove it.¹⁷ The extraction method is easier to use than the ultrasonic technique, but it has some disadvantages as well. The trephines are too large compared with the size of the fragments that are usually found in the root canal. The smallest available diameter is 1.1 mm, whereas the diameter of the extractor is 1.2 mm, which means that it has to be used with a trephine of the same diameter. Depending on the position of the fragment in the root, a large quantity of dentine might have to be removed, which is likely to weaken the root.

Some improvement to the Masserann's extractor was made with the introduction of the IRS. However, in the described technique,¹⁸ access to the fragment was accomplished with ultrasonic tips. The use of ultrasonic tips to disengage the fragment results in an over-enlarged access compared with the size of the IRS extractor. This reduces the interest to use smaller extractors, which are fragile and may deform.

Compared with the Masserann Micro Kit, the Endo Rescue Kit has a number of special features. The first feature is a centring drill with the same diameter as the trephine. Owing to its active concave tip, the outer blades trough around the fragment, and allow centring of the preparation. The second feature is the miniaturisation of the trephines. Three trephines are available: the smallest trephine has an external diameter of 0.7 mm (internal diameter of 0.4 mm), the size of the next one is 0.9 mm (internal diameter of 0.5 mm), and the last one is 1.1 mm (internal diameter of 0.7 mm). Compared with the Masserann's trephines, the sizes are considerably smaller. The largest size trephine drill in the Endo Rescue Kit corresponds to the smallest size in the Masserann Micro Kit. The trephines are designed to be used with an anti-clockwise motion in order to have an unscrewing effect on the fragment. This feature is particularly useful for NiTi rotary fragments, which are usually screwed into the dentine. When the fragment is short (less than 3 mm), it is often pulled out of the canal with the trephine drill. In this instance, it is trapped by the dentinal chips inside the lumen of the trephine. When the fragment is longer than 3 mm or when the tip is located beyond the curvature, the action of the trephine should be stopped before grinding the fragment with the active part of the trephine. The direction of rotation must be considered too, depending on the type of fractured instrument. Rotary instruments used for obturation, such as Lentulo spirals or McSpadden compactors,

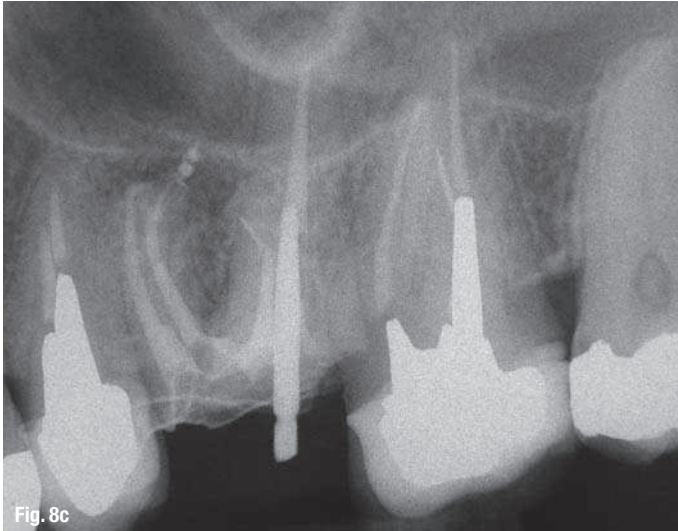


Fig. 8c

Fig. 8c_Cleaning, shaping and filling of the root canal system.

Fig. 8d_One year recall: tooth is symptomless.

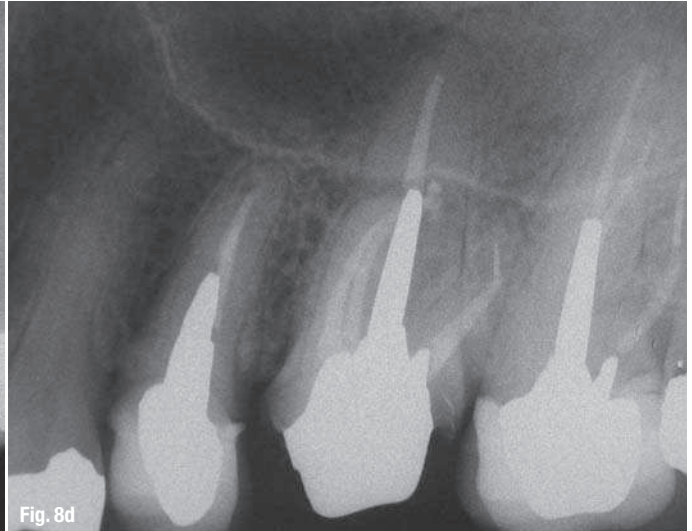

Fig. 8d

or shaping instruments that work in a reciprocating motion, should be disengaged with a clockwise motion because their helix angle is reversed.

The micro-tube coupled with the Hedstroem file technique⁹ is another way to create an extractor that is more adaptable to the clinical situation using different size tubes and files.

Using tubes and glue is also advocated to grasp the fragment with cyanoacrylate glue (Cancellier Kit) or composite self-curing resin.¹⁹ Needles of different diameters may be used to match the size of the broken instrument. This can only occur if the coronal part of the fragment has been freed from the dentinal walls. This technique is predictable but three problems have been reported. The first is that, to ensure that the cavity is clean and dry, the cavity must be rinsed with pure alcohol and be perfectly dry before using the needle filled with composite resin. The second is that the operator must ensure that the needle is filled with resin in order to surround the fragment. The third is that the operator must ensure that the resin does not overflow from the needle and remains inside the root canal. These problems can be easily overcome however. The composite resin was injected into the needle. The hub of the needle was then plugged with wax until the resin emerged from the tip. The tip was wiped with gauze to ensure that there was no resin on the outer walls of the needle. In this way, the resin can surround the fragment without any overflow. In the study, this technique was performed using a needle of the same diameter as the trephine for 12 of the 29 fragments. Ten of the 12 fragments were removed without leaving any composite resin to potentially block the root canal. Two failures occurred because the fragments were further fractured, leaving the most apical part in the canal and the coronal part embedded in the resin.

_Conclusion

Several techniques for removing fractured instruments have been described. Any procedure for removing fractured instruments should seek to avoid damage to the root structure, and should be predictable. The removal technique investigated in the present study, based on the use of a micro-tube and preparation of a staging platform by means of new centring drills, was shown to be effective for the removal of fractured instruments. Although no technique can claim to be universal, the technique described in the study proposes a removal solution well suited to fractured NiTi rotary instruments and offers an alternative to the ultrasonic tips technique. Like any endodontic technique, the Endo Rescue Kit is a technique-sensitive approach and requires clinical experience to be used successfully. However, this preliminary study reported few cases and therefore further studies must be conducted to corroborate these results. The location of the instrument within the root canal, the angle of curvature of the affected root and the location of the broken instrument in relation to the root curvature appear to be decisive factors for the outcome of the removal technique.

Editorial note: A complete list of references is available from the publisher.

_contact

roots

Dr Dominique Martin

21 rue Fabre d'Églantine
75012 Paris
France

endomartin@wanadoo.fr